

Laerdal SonoSim Ultrasound Solution (LSUS) 2.0 SimMan Cardiac Resuscitation Bundle Peer-to-Peer Checklist

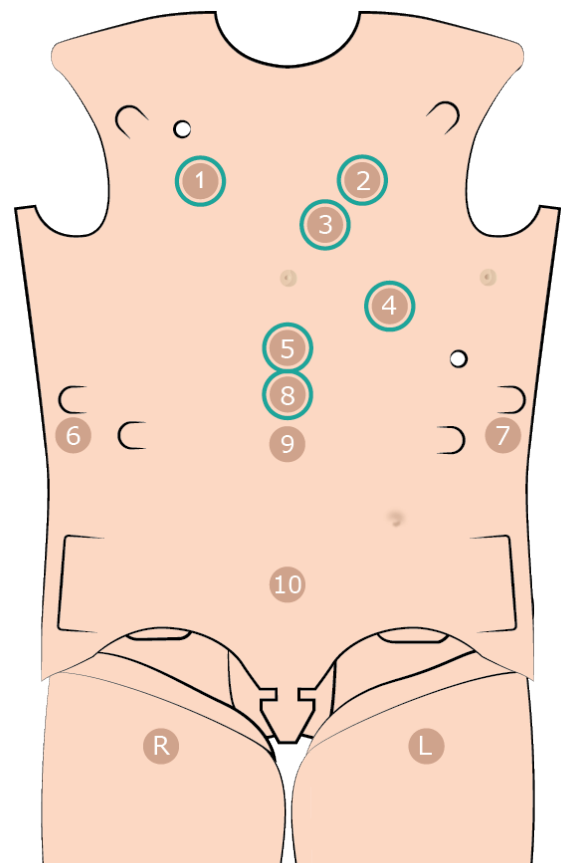
Cardiac Resuscitation bundle contains 10 different actual patient cases as part of the patient assessment and diagnosis.

Target group(s): Healthcare providers that participate in the care of critically ill patients and senior medical students.

Use: Each case checklist outlines the findings for each ultrasound window available for that case. Have the participant scan each location and verbalize their findings and confirm these with the checklist. For a comprehensive, expert-narrated summary of each ultrasound window finding, select the *Findings* tab located in the right menu. The locations highlighted in blue are the sites where ultrasound images can be seen.

Cardiac Resuscitation Bundle Active Tags:

1. Right Chest
2. Left Chest
3. Parasternal
4. Apical
5. Subcostal
6. Right Upper Quadrant
7. Left Upper Quadrant
8. Proximal IVC
9. Mid Aorta
10. Suprapubic
Right Groin
Left Groin



Case I

Provide the following case summary - 60-year-old male who suffered a witnessed, non-traumatic cardiac arrest and presents via paramedic ambulance after receiving cardiopulmonary resuscitation and initial dose of epinephrine.

Initial Observations: HR: chest compressions in progress / RR:15 ventilated via endotracheal tube / BP: N/A / Temp: 37C / SPO2-unreliable

Ultrasound Findings:

Ultrasound Window	Findings	Correct Interpretation Yes/No
Parasternal	No pericardial effusion; Decreased contractility; Normal chamber size ratio	
Apical	No pericardial effusion; Decreased contractility; Normal chamber size ratio	
Subcostal	No pericardial effusion; Decreased contractility, Normal chamber size ratio	
Proximal IVC	IVC diameter less than or equal to 2.1 cm; Respirophasic collapse less than or equal to 50%; Right atrial pressure 5 to 10 mmHg	
Right Chest	Positive lung sliding; Multiple B-lines (evidence of alveolar interstitial syndrome); Pleural defect	
Left Chest	Positive lung sliding; Multiple B-lines (evidence of alveolar interstitial syndrome); Pleural effusion	

Clinical Diagnosis – Pulseless electrical activity; hyperkalemia.

Case 2

Provide the following case summary - 66-year-old male who presents with non-radiating, non-migratory, left-sided chest pain.

Initial Observations: HR: 90 / RR:22 / BP: 220/120 / Temp: 37C / SPO2-97% on room air

Ultrasound Findings:

Ultrasound Window	Findings	Correct Interpretation Yes/No
Parasternal	No pericardial effusion; Decreased contractility, Normal chamber size ratio; Small anterior fat pad	
Apical	No pericardial effusion; Decreased contractility; Markedly dilated aortic root	
Subcostal	No gross pericardial effusion, Limited view of heart	
Proximal IVC	IVC diameter greater than 2.1 cm; Respirophasic collapse greater than 50%; Right atrial pressure 10 to 15 mmHg	
Right Chest	Positive lung sliding; Occasional scattered B-lines; No evidence of pneumothorax or alveolar interstitial syndrome	
Left Chest	Positive lung sliding; Occasional scattered B-lines; No evidence of pneumothorax or alveolar interstitial syndrome	

Clinical Diagnosis – Acute ascending aortic dissection; thoracic aortic aneurysm

Case 3

Provide the following case summary - 58-year-old male who presents after experiencing a witnessed syncopal episode lasting several minutes.

Initial Observations: HR: 130 / RR:30 / BP: 70/40 / Temp: 37C / SPO2-87% on face mask non-rebreather

Ultrasound Findings:

Ultrasound Window	Findings	Correct Interpretation Yes/No
Parasternal	No pericardial effusion; Normal left ventricular contractility, Dilated and hypokinetic right ventricle; Positive leftward septal deviation (D-sign); Limited near field view	
Apical	No pericardial effusion; Normal left ventricular contractility; Dilated right atrium; Dilated and hypokinetic right ventricle; Limited view left atrium	
Subcostal	No pericardial effusion, Dilated right atrium	
Proximal IVC	IVC diameter greater than 2.1 cm; Respirophasic collapse less than or equal to 50%; Right atrial pressure 15 to 20 mmHg	
Right Chest	Positive lung sliding; Occasional scattered B-lines; No evidence of pneumothorax or alveolar interstitial syndrome	
Left Chest	Positive lung sliding; No evidence of pneumothorax or alveolar interstitial syndrome	

Clinical Diagnosis – Massive pulmonary embolus

Case 4

Provide the following case summary - 62-year-old male undergoing chemotherapy for multiple myeloma, who presents complaining of generalized weakness and shortness of breath. He has had a progressive mental-status decline over the past 24 hours.

Initial Observations: HR: 130 / RR:30 / BP: 68/38 / Temp: 35.8C / SPO2-90% on 4L via nasal cannula

Ultrasound Findings:

Ultrasound Window	Findings	Correct Interpretation Yes/No
Parasternal	No pericardial effusion; Normal-to-hyperdynamic contractility, Normal chamber size ratio; Anterior fat pad	
Apical	No pericardial effusion; Normal-to-hyperdynamic contractility, Normal chamber size ratio	
Subcostal	No pericardial effusion; Normal-to-hyperdynamic contractility, Normal chamber size ratio	
Proximal IVC	IVC diameter greater than or equal to 2.1cm; Respirophasic collapse greater than 50%; Right atrial pressure 0 to 5 mmHg	
Right Chest	Positive lung sliding; Multiple B-lines (evidence of alveolar interstitial syndrome); Pleural defect	
Left Chest	Positive lung sliding; scattered B-lines; (evidence of alveolar interstitial syndrome)	

Clinical Diagnosis – Severe sepsis with pulmonary source of infection

Case 5

Provide the following case summary - 55-year-old male, with history of coronary artery disease, who presents after a syncopal episode that occurred while he was eating dinner at a restaurant. The patient reports having chest tightness, abdominal pain, shortness of breath, and diffuse weakness. He has no known allergies.

Initial Observations: HR: 130 / RR: 30 / BP: 72/42 / Temp: 37C / SPO2-93% on room air

Ultrasound Findings:

Ultrasound Window	Findings	Correct Interpretation Yes/No
Parasternal	No pericardial effusion; Mildly decreased contractility; Normal chamber size ratio	
Apical	No pericardial effusion; Mildly decreased contractility; Normal chamber size ratio	
Subcostal	No pericardial effusion; Mildly decreased contractility; Normal chamber size ratio	
Proximal IVC	IVC diameter less than or equal to 2.1 cm; Respirophasic collapse greater than 50%; Right atrial pressure 0 to 5 mmHg	
Right Chest	Positive lung sliding; No evidence of alveolar interstitial syndrome or pneumothorax	
Left Chest	Positive lung sliding; No evidence of alveolar interstitial syndrome or pneumothorax	

Clinical Diagnosis – Anaphylaxis

Case 6

Provide the following case summary - 30-year-old male who presents with altered sensorium after being found down in a retail store. Paramedics established intravenous (IV) access. No further history is available at this time.

Initial Observations: HR: 85 / RR: 20 / BP: 155/84 / Temp: 37C / SPO2-94% on room air

Ultrasound Findings:

Ultrasound Window	Findings	Correct Interpretation Yes/No
Parasternal	No pericardial effusion; Normal contractility; Severe concentric left ventricular hypertrophy; Hypertrophic cardiomyopathy; Pacemaker/AICD wire visualized in right atrium and right ventricle	
Apical	No pericardial effusion; Normal contractility; Severe concentric left ventricular hypertrophy; Hypertrophic cardiomyopathy; Pacemaker/AICD wire visualized in right atrium and right ventricle	
Subcostal	Limited view of heart	
Proximal IVC	IVC diameter less than or equal to 2.1 cm; Respirophasic collapse less than or equal to 50%; Right atrial pressure 5 to 10 mmHg	
Right Chest	Positive lung sliding; Occasional scattered B-lines; No evidence of pneumothorax or alveolar interstitial syndrome	
Left Chest	Positive lung sliding; Occasional scattered B-lines; No evidence of pneumothorax or alveolar interstitial syndrome	

Clinical Diagnosis – Cardiac syncope; hypertrophic cardiomyopathy

Case 7

Provide the following case summary - 58-year-old male with a past medical history of dialysis- dependent chronic renal insufficiency, who presents from a dialysis center complaining of weakness and shortness of breath.

Initial Observations: HR: 126 / RR: 24 / BP: 71/53 /Temp: 37C / SPO2-100% on 2L nasal cannula oxygen

Ultrasound Findings:

Ultrasound Window	Findings	Correct Interpretation Yes/No
Parasternal	Large pericardial effusion; Swinging heart; Diastolic collapse of right ventricle; Pleural effusion	
Apical	Large pericardial effusion; Swinging heart; Diastolic collapse of right ventricle	
Subcostal	Large pericardial effusion; Limited view of heart	
Proximal IVC	IVC diameter greater than 2.1 cm; Respirophasic collapse less than or equal to 50%; Right atrial pressure 15 to 20 mmHg	
Right Chest	Positive lung sliding; No evidence of pneumothorax or alveolar interstitial syndrome	
Left Chest	Positive lung sliding; Occasional scattered B-lines; No evidence of pneumothorax or alveolar interstitial syndrome	

Clinical Diagnosis – Cardiac tamponade

Case 8

Provide the following case summary - 86-year-old male who presents with a complaint of generalized weakness, progressive over one week. Today he felt so weak that he was unable to get out of bed.

Initial Observations: HR: 105 / RR: 22 / BP: 85/42 / Temp: 37C / SPO2-93% on room air

Ultrasound Findings:

Ultrasound Window	Findings	Correct Interpretation Yes/No
Parasternal	Circumferential pericardial effusion; Normal contractility; No echocardiographic evidence of cardiac tamponade	
Apical	Circumferential pericardial effusion; Normal contractility; No echocardiographic evidence of cardiac tamponade	
Subcostal	Circumferential pericardial effusion; Normal contractility; No echocardiographic evidence of cardiac tamponade	
Proximal IVC	IVC diameter less than or equal to 2.1 cm; Respirophasic collapse less than or equal to 50%; Right atrial pressure 5 to 10 mmHg	
Right Chest	Positive lung sliding; Occasional scattered B-lines; No evidence of pneumothorax or alveolar interstitial syndrome	
Left Chest	Positive lung sliding; Occasional scattered B-lines; No evidence of pneumothorax or alveolar interstitial syndrome	

Clinical Diagnosis – Hypotension; dehydration; electrolyte imbalance

Case 9

Provide the following case summary - 75-year-old male who presents with shortness of breath, worsening over three hours. He reports having chest pain over the same period of time.

Initial Observations: HR: 115 / RR: 30 / BP: 95/70 / Temp: 37.8C / SPO2-90% on 2L via nasal cannula

Ultrasound Findings:

Ultrasound Window	Fidings	Correct Interpretation Yes/No
Parasternal	No pericardial effusion; Normal contractility; Normal chamber size ratio; Pleural effusion	
Apical	No pericardial effusion; Normal contractility; Normal chamber size ratio	
Subcostal	No pericardial effusion; Normal contractility; Normal chamber size ratio	
Proximal IVC	IVC diameter less than or equal to 2.1 cm; Respirophasic collapse less than or equal to 50%; Right atrial pressure 5 to 10 mmHg	
Right Chest	No lung sliding; Barcode sign; Suggestive of pneumothorax	
Left Chest	Positive lung sliding; No evidence of pneumothorax or alveolar interstitial syndrome	

Clinical Diagnosis – Tension pneumothorax

Case 10

Provide the following case summary - 62-year-old male who presents with complaints of chest pain radiating to his left shoulder for six hours. It varies in intensity, is somewhat worse with activity, and is associated with dyspnea.

Initial Observations: HR: 98 / RR: 23 / BP: 103/60 / Temp: 37.7C / SPO2-93% on room air

Ultrasound Findings:

Ultrasound Window	Fidings	Correct Interpretation Yes/No
Parasternal	No pericardial effusion; Decreased contractility; Dilated left ventricle; Thin interventricular septal walls; No right ventricle strain; Pacer wire visualized in right atrium and right ventricle	
Apical	No pericardial effusion; Decreased contractility; Dilated left ventricle; Thin interventricular septal walls; No right ventricle strain; Pacer wire visualized in right atrium and right ventricle	
Subcostal	No pericardial effusion; Decreased contractility; Dilated left ventricle; Thin interventricular septal walls; No right ventricle strain; Pacer wire visualized in right atrium and right ventricle	
Proximal IVC	IVC diameter greater than 2.1 cm; Respirophasic collapse less than or equal to 50%; Right atrial pressure 15 to 20 mmHg	
Right Chest	Positive lung sliding; Occasional scattered B-lines; Pleural line defect; Small Pleural Effusion	
Left Chest	Positive lung sliding; Occasional scattered B-lines; No evidence of pneumothorax or alveolar interstitial syndrome	

Clinical Diagnosis – Acute coronary syndrome